

Additional Diagnostic Value of Systolic Dysfunction Induced by Dipyridamole Stress Cardiac Magnetic Resonance Used in Detecting Coronary Artery Disease

Oliver Husser,^a Vicente Bodí,^a Juan Sanchís,^a Luis Mainar,^a Julio Núñez,^a Maria P. López-Lereu,^b José V. Monmeneu,^b Vicente Ruiz,^a Eva Rumiz,^a David Moratal,^c Francisco J. Chorro,^a and Ángel Llácer^a

^aServicio de Cardiología, Hospital Clínico Universitario, Universitat de València, Valencia, Spain

^bUnidad de Resonancia Magnética Cardiovascular, ERESA, Valencia, Spain

^cCentro de Biomateriales e Ingeniería Tisular, Universitat Politècnica de València, Valencia, Spain

Introduction and objectives. Dipyridamole stress perfusion cardiac magnetic resonance (CMR) is used to detect coronary artery disease (CAD). However, few data are available on the diagnostic value of the systolic dysfunction induced by dipyridamole. This study investigated whether the induction of systolic dysfunction supplements the diagnostic information provided by perfusion imaging in the detection of CAD.

Methods. Overall, 166 patients underwent dipyridamole CMR and quantitative coronary angiography, with CAD being defined as a stenosis $\geq 70\%$. Systolic dysfunction at rest, systolic dysfunction with dipyridamole, induced systolic dysfunction, and stress first-pass perfusion deficit (PD) and delayed enhancement were quantified.

Results. In the multivariate analysis, PD (hazard ratio [HR] =1.6; 95% confidence interval [CI], 1.33-1.91; $P < .0001$) and induced systolic dysfunction (OR=1.8; 95% CI, 1.18-2.28; $P < .007$) were independently associated with CAD and had a sensitivity and specificity of 92% and 62% and 43% and 96%, respectively. Patients were categorized as having no ischemia (Group 1), PD but no induced systolic dysfunction (Group 2), or induced systolic dysfunction irrespective of PD (Group 3). In Group 3, the prevalence of CAD was higher than in Group 1 or 2 (96% vs 22% and 79%, respectively; $P = .001$) and the risk of CAD was 2-fold higher than in Group 2 (OR=2.34; 95% CI, 1.07-5.13; $P = .034$). Compared with Group 2, more hypoperfused segments were observed in Group 3 (6.2 [2.6] vs 7.4 [3.4]; $P = .044$), and more diseased vessels (1.4 [1.0] vs 1.8 [0.9]; $P = .036$). Adding induced systolic dysfunction to perfusion and clinical data improved the multivariate model's C-statistic for predicting CAD (0.81 vs 0.87; $P = .02$).

Conclusions. Combining induced systolic dysfunction with perfusion imaging increases the diagnostic accuracy of detecting CAD and enables patients with severe ischemia and a high probability of CAD to be identified.

Key words: Cardiovascular magnetic resonance. Perfusion. Wall motion. Dipyridamole. Coronary artery disease.

Valor diagnóstico adicional de la disfunción sistólica inducida para la detección de enfermedad coronaria mediante resonancia magnética cardiaca de estrés con dipiridamol

Introducción y objetivos. La perfusión con dipiridamol en resonancia magnética cardiaca (RMC) de estrés se utiliza para la detección de enfermedad de las arterias coronarias (EAC). Sin embargo, se carece de información sobre el valor diagnóstico de la disfunción sistólica (DS) inducida con dipiridamol. Este estudio se centra en investigar si la DS inducida aporta un valor diagnóstico adicional junto con la perfusión para la detección de las EAC.

Métodos. Se sometió a 166 pacientes a una RMC con dipiridamol y a una angiografía coronaria cuantitativa. Se definió EAC para valores $\geq 70\%$ de estenosis. Se analizó la extensión de la DS en reposo, la DS con dipiridamol, la DS inducida, el déficit de perfusión (DP) de primer paso en estrés y el realce tardío.

Resultados. En un análisis multivariable, el DP (1,6 [1,33-1,91]; $p < 0,0001$) y la DS inducida (1,8 [1,18-2,28]; $p < 0,007$) se relacionaron independientemente con la EAC y tuvieron sensibilidades/especificidades del 92%/62% y el 43%/96%, respectivamente. Los pacientes se clasificaron en grupo 1, sin isquemia, grupo 2, DP pero sin DS inducida, y grupo 3, DS inducida independientemente del DP. El grupo 3 presentó una mayor prevalencia de EAC que los grupos 1 y 2 (el 96 frente al 22 frente al 79%; $p = 0,001$) y un riesgo de EAC dos veces mayor (2,34 [1,07-5,13]; $p = 0,034$) que el grupo 2. Comparado con el grupo 2, el grupo 3 presentó más segmentos hipoperfundidos (6,2 \pm 2,6 frente a 7,4 \pm 3,4; $p = 0,044$) y más vasos patológicos (1,4 \pm 1 frente a 1,8 \pm 0,9; $p = 0,036$). Añadiendo la DS inducida a la perfusión y a la información clínica, se mejoró el test estadístico C del modelo multivariable para predecir la EAC (0,81 frente a 0,87; $p = 0,02$).

Conclusiones. La DS inducida, junto con la imagen de perfusión, ofrece un valor diagnóstico adicional para la detección de EAC y permite la identificación de pacientes con isquemia severa y alta probabilidad de EAC.

SEE EDITORIAL ON PAGES 350-3

Correspondence: Dr. V. Bodí.
Servicio de Cardiología. Hospital Clínico y Universitario de Valencia.
Blasco Ibáñez, 17. 46010 Valencia. España.
E-mail: vicentbodi@hotmail.com

Received May 5, 2008.

Accepted for publication December 11, 2008.

Palabras clave: Resonancia magnética cardiovascular. Perfusión. Movimiento de la pared. Dipyridamol. Enfermedad de las arterias coronarias.

ABBREVIATIONS

AWM: abnormal wall motion
CAD: coronary artery disease
CMR: cardiovascular magnetic resonance
DE = delayed enhancement
PD: perfusion deficit

INTRODUCTION

Stress perfusion cardiac magnetic resonance imaging (CMR) is used for the evaluation of patients suspected of having coronary artery disease (CAD) in daily clinical practice.¹

In one setting, CMR allows the assessment of abnormal wall motion (AWM) and myocardial perfusion deficits (PD), 2 important parameters used for diagnosis of significant CAD.²⁻⁵ The sequential occurrence of these 2 phenomena during myocardial ischemia is part of what has been described as the "ischemic cascade."^{6,7}

Nevertheless, since the advent of myocardial perfusion imaging using vasodilators, the focus of attention has shifted away from stress inducible AWM to stress induced PD using CMR. Perfusion studies at stress have yielded promising results with a high accuracy for the detection of angiographic significant coronary lesions.^{4,8} CMR offers good temporal and excellent spatial resolution advocating this modality for the assessment of subtle changes in myocardial contractility during pharmacological stress, however there is little data on the diagnostic use of AWM at vasodilator stress for the detection of significant angiographic lesions.⁹

We have recently reported that the extent of AWM at peak dipyridamole stress is the CMR index most closely related to prognosis in patients with chest pain of possible coronary origin undergoing stress CMR.¹⁰ The objective of the present study was to analyze if inducible AWM affords additional diagnostic value for the detection of CAD.

METHODS

Study Group

Out of a total population of 600 patients who underwent stress CMR at our institution between January 2003 and May 2007, we retrospectively examined a study population of 166 patients (51

TABLE 1. Clinical Characteristics (n=166)

Male sex (%)	115 (69)
Age, mean (SD), y	65 (11)
Diabetes, n (%)	64 (39)
Hypertension, n (%)	109 (66)
Hypercholesterolemia, n (%)	90 (54)
Smoker, n (%)	34 (21)
Previous IHD, n (%)	91 (55)
Previous MI, n (%)	45 (27)
Previous PTCA, n (%)	26 (16)
Previous bypass, n (%)	19 (11)
LVEF, %	60 (13)
LVEDD, mm	69 (23)
LVESD, mm	31 (25)

IHD indicates ischemic heart disease; LVEF, left ventricular ejection fraction; LVEDD, left ventricular end-diastolic diameter; LVESD, left ventricular end-systolic diameter; MI, myocardial infarction; PTCA, percutaneous transluminal coronary angioplast. The data express mean (SD) or n (%).

women (31%); age, 65 (11); range, 30-85; see Table 1) with chest pain of possible coronary origin who underwent dipyridamole stress CMR and coronary angiography within 3 months before or after CMR. The majority (88%) of the patients underwent coronary angiography after CMR imaging. Patients underwent CMR studies because of inconclusive exercise testing in 18% cases, abnormal ECG at rest in 26%, inability to exercise in 28%, and as the first choice for ischemia evaluation in 28% of the cases. Twenty patients (12%) underwent CMR examination after coronary angiography due to evaluation of intermediate lesions. Patients, who had undergone a coronary revascularization, had had a myocardial infarction within 3 months before the CMR study or any contraindication for dipyridamole were excluded from analysis. The study protocol was approved by the local ethics committee and all subjects gave informed consent.

CMR Study

All patients were examined with a 1.5-T system (Sonata Magnetom, Siemens, Erlangen, Germany) using a previously described CMR protocol¹⁰ (Figure 1). All images were acquired by a phased-array body surface coil during breath holds and were electrocardiogram triggered.

Cine Images at Rest

Left ventricular function was assessed using cine images in 2-, 3-, 4 chamber, and short-axis views using a true fast imaging with steady-state precession sequence (SSFP) (repetition time/ echo time 2.8 ms/1.2 ms, flip angle 58°, matrix 256 × 256, field of view 320 × 270 mm, slice thickness 6 mm). In

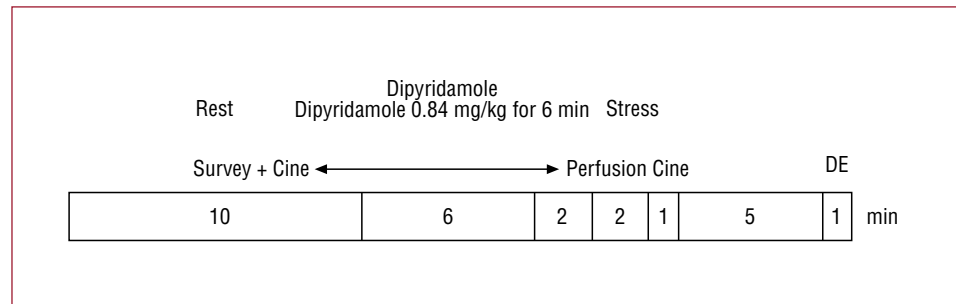


Figure 1. Dipyridamole stress cardiac magnetic resonance study protocol. DE indicates delayed enhancement.

each patient, of the stack of short-axis views of cine images at rest, we selected 3 reference locations at base, mid-ventricle and apex which were repeated to assess perfusion, wall motion at stress and delayed enhancement.

First Pass Perfusion Imaging

Vasodilatation was induced with dipyridamole (0.56 mg/kg body weight over 4 min and if well tolerated by the patient up to 0.84 mg/kg delivered intravenously over 6 min). After the end of dipyridamole infusion, 0.1 mmol/kg gadopentate dimeglumine (Magnograf, Schering, Berlin, Germany) was injected intravenously at a speed of 5 mL/s. Then 5 sections equally separated in the short-axis view and 2 in the 2- and 4-chamber long-axis views were acquired for first-pass perfusion imaging every other heart beat (SSFP with a notched saturation pulse; inversion time, 125 ms; repetition time/echo time, 202 ms/1 ms; flip angle, 50°; matrix, 192 × 96; field of view, 350 × 220 mm; slice thickness, 8 mm).

Cine Images at Stress

Once peak myocardial enhancement was reached, to assess left ventricular function within the peak dipyridamole-induced vasodilatation (approximately 2-3 min after infusion) we used a fast-acquisition multislice SSFP cine image sequence (repetition time/echo time, 35 ms/1.1 ms; flip angle, 65°; matrix, 192 × 159; field of view, 350 × 304 mm; slice thickness, 8 mm) acquiring over a 14-s period in a single breath hold 4 slices in the short-axis view including the same 3 reference locations defined in the cine images at rest.

Delayed Enhancement Imaging

Delayed enhancement imaging was performed 10 min after contrast injection in the same locations evaluated for cine images at rest (segmented inversion recovery SSFP; repetition time/echo time, 700 ms/1.26 ms; flip angle, 45°; matrix, 256 × 184; field of view, 340 × 235 mm; slice thickness, 8 mm). The inversion time was adjusted to null normal myocardium.

CMR Data Analysis

CMR studies were analyzed by an experienced observer (M.P.L.L., 8 years of experience) blinded to all angiographic and patient data and unaware of the chronological order of the 2 examinations, using customized software (Syngo, Siemens, Erlangen, Germany). Left ventricular end-diastolic and end-systolic diameter (mm) and ejection fraction (Simpson method, %) were quantified by direct planimetry of left ventricular contours in the stack of short-axis cine images at rest. Segments location was defined in cine-images sequences applying the 17-segment model.¹¹ We evaluated 5 dipyridamole stress CMR-derived indexes:

1. AWM at rest (AWM-rest). Number of segments showing hypokinesis, akinesis, or dyskinesis at baseline.¹²
2. AWM with dipyridamole (AWM-D). Number of segments showing hypokinesis, akinesis, or dyskinesis at stress.
3. Inducible AWM. Number of segments in which wall motion worsened with dipyridamole from normokinesis to hypokinesis or from hypokinesis to akinesis.
4. PD with dipyridamole. Number of segments showing a persistent delay (in at least 3 consecutive temporal images, compared to the other segments in the same slice) in the visual analysis of the enhancement pattern during the first pass of contrast through the myocardium.¹³
5. Delayed enhancement (DE). Number of segments showing enhancement in delayed enhancement imaging.

In a group of 20 patients evaluated for ischemic chest pain and not included in this study, interobserver agreement for the presence or absence of >1 segment with abnormal CMR indexes was as follows: AWM, 95%; AWM-D, 95%; abnormal perfusion, 90%; and delayed enhancement, 100%.¹⁰

According to the pathophysiologic considerations of the ischemic cascade^{6,7} patients were categorized into 3 groups (Figure 2):

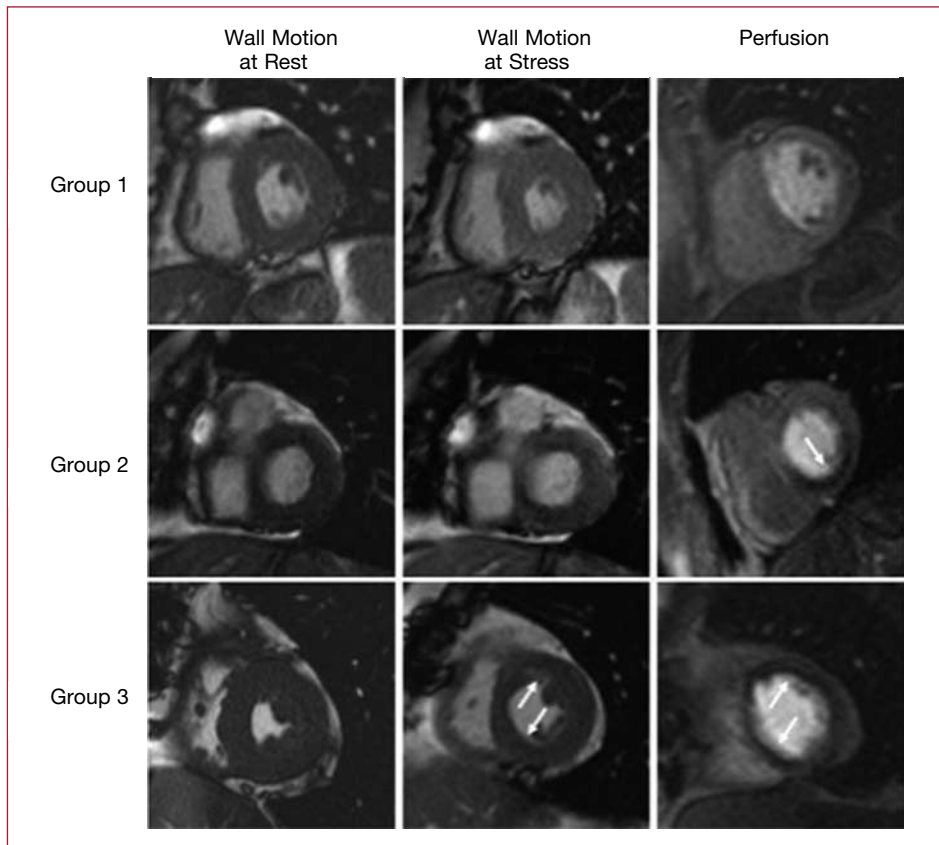


Figure 2. Group 1: example of a patient with no evidence of ischemia. Group 2: example of a patient with perfusion deficit in the inferior area (arrow) without inducible abnormal wall motion. Group 3: example of a patient with simultaneous perfusion deficit and inducible abnormal wall motion in all territories (arrows).

- Group 1: No evidence of ischemia. Normal perfusion study and no inducible AWM
- Group 2: Abnormal perfusion study but no inducible AWM
- Group 3: Inducible AWM present regardless of PD

Coronary Angiography

Angiographic data was evaluated by an experienced cardiologist (V.B., 8 years of experience), blinded to all CMR and patient data and unaware of the chronological order of the 2 examinations, using quantitative coronary angiography on a standard digital imaging system (HM3000, Philipps, Best, The Netherlands). CAD was defined as $\geq 70\%$ narrowing of the coronary lumen of 1 of the 3 major coronary arteries (or in a principal branch measuring ≥ 2 mm in diameter) or as $\geq 50\%$ narrowing of the left main artery.

Statistical Analysis

Continuous data is expressed as the mean (standard deviation), and was compared by the unpaired *t* test. Categorical variables were compared with the χ^2 test. For calculation of sensitivity, specificity,

positive predictive value, and negative predictive value variables were categorized according to the best cut-off value obtained in receiver-operating characteristic (ROC) curve analysis (0-1 segment vs >1 segment for AWM-rest, AWM-D, inducible AWM and DE; 0-2 segments vs >2 segments for PD). The higher cut-off value for PD was chosen due to susceptibility to artifacts and the inherent very high sensitivity and lower specificity of this index. The association of CMR with angiographic data was assessed with a forward logistic regression model adjusted for clinical parameters showing a *P*value $<.2$ in univariate analysis. For the 3 different groups another logistic regression was performed, also adjusted by clinical parameters with a *P* $<.2$ in univariate analysis. Odds ratios (OR) with 95% confidence interval (95% CI) were obtained. The additional value of inducible AWM was assessed by comparing the C-statistic of a model including baseline characteristics and PD with a model resulting by adding inducible AWM. A *P* value less than .05 was considered statistically significant. SPSS statistical package (Version 13.0, SPSS Inc, Chicago, Illinois, USA) and STATA (Version 9.0, StataCorp, College Station, Texas, USA) were used.

TABLE 2. Comparison of Clinical Parameters and Cardiovascular Magnetic Resonance Imaging Data of Patients With and Without Coronary Artery Disease

	No CAD (n=47)	CAD (n=119)	P
Male sex, n (%)	30 (64)	89 (75)	.02
Age, mean (SD), y	63 (13)	66 (10)	.2
Diabetes, n (%)	15 (32)	49 (41)	.3
Hypertension, n (%)	26 (55)	83 (70)	.1
Hypercholesterolemia, n (%)	23 (49)	67 (57)	.5
Smoker, n (%)	12 (26)	22 (19)	.3
Previous IHD, n (%)	20 (43)	71 (60)	.06
Previous MI, n (%)	11 (23)	34 (29)	.6
Previous PTCA, n (%)	7 (15)	19 (16)	.5
Previous bypass (%)	4 (9)	15 (13)	.6
LVEF, %	62 (11)	59 (14)	.1
LVEDD, mm	71 (25)	68 (22)	.4
LVESD, mm	32 (34)	30 (21)	.6
AWM-rest	1.4 (3.0)	2.6 (3.5)	.03
AWM-D	1.6 (3.2)	4.9 (4)	<.001
Inducible AWM	0.2 (0.8)	2.2 (3)	<.001
PD	2.2 (2.5)	6.5 (3.4)	<.001
DE	0.8 (1.9)	2.3 (2.8)	<.001

AWM-rest indicates abnormal wall motion at rest; AWM-D, abnormal wall motion with dipyridamole; CAD, coronary artery disease; DE, delayed enhancement; IHD, ischemic heart disease; LVEF, left ventricular ejection fraction; LVEDD, left ventricular end-diastolic diameter; LVESD, left ventricular end-systolic diameter; MI, myocardial infarction; PTCA, percutaneous transluminal coronary angioplasty; PD, perfusion deficit. The data express mean (SD) or n (%).

RESULTS

Stress CMR data and angiographic data of all 166 patients were evaluated. During the CMR examination, 31% of the patients experienced an episode of chest pain, 4% displayed shortness of breath, 1% had headache, and 2% of the patients experienced nausea during the examination. Heart rate at baseline was 68 (12) bpm and 85 (13) bpm after dipyridamole stress ($P<.0001$). Systolic and diastolic blood pressure at baseline was 144 (24)/84 (14) mm Hg and 140 (25)/81 (14) mm Hg after the examination ($P=.059$ and $P=.07$, respectively). Mean left ventricular ejection fraction determined by CMR was 61% (13%). Coronary angiography was performed within 3 month before or after the CMR study (mean time window 16 [32] days). No patient experienced any cardiac event between the 2 examinations.

CMR Results

Magnetic resonance examinations revealed at least 1 abnormal CMR index in 139 patients (84%). Sixty-nine (42%) of the patients had AWM-rest. Four hundred (63%) displayed AWM-D. In 53 (32%) of the patients inducible AWM was observed, 128 (77%)

of the patients displayed PD, and 68 (41%) patients had abnormal delayed enhancement imaging.

Angiographic Results

Coronary angiography was abnormal in 119 patients (72%). Coronary angiography detected 209 significant coronary lesions (67 in the left anterior descending artery, 65 in the circumflex artery, and 77 in the right coronary artery). There were 58 patients (35%) with 1-vessel disease, 33 patients (20%) had 2-vessel disease, and 29 patients (17%) had 3-vessel disease.

Detection of CAD

A comparison of patients with and without CAD is displayed in Table 2. Patients with an abnormal angiography were mostly of male gender and tended to have a history of previous ischemic heart disease. Patients with angiographic CAD displayed a significant larger extent of all 5 CMR indexes. The diagnostic performance of the 5 CMR indexes for detecting CAD is displayed in Table 3. In the multivariate analysis, adjusted for clinical parameters, PD (1.6 [1.33-1.91]; $P<.0001$, per segment), inducible AWM (1.8 [1.18-2.28]; $P<.007$,

TABLE 3. Detection of Coronary Artery Disease Diagnostic Performance of the CMR Parameters for Detection of Coronary Artery Disease (n=166)

	Sensitivity (95% CI)	Specificity (95% CI)	PPV (95% CI)	NPV (95% CI)
AWM-rest	0.49 (0.40-0.58)	0.77 (0.65-0.89)	0.84 (0.75-0.93)	0.37 (0.26-0.49)
n/No.	58/119	36/47	58/69	36/97
AWM-D	0.77 (0.60-0.85)	0.72 (0.69-0.84)	0.88 (0.81-0.94)	0.55 (0.45-0.64)
n/No.	91/119	34/47	91/104	34/62
Inducible AWM	0.43 (0.34-0.52)	0.96 (0.90-1.0)	0.96 (0.91-1.0)	0.40 (0.27-0.53)
n/No.	51/119	45/47	51/53	45/113
PD	0.92 (0.88-0.97)	0.62 (0.48-0.76)	0.86 (0.80-0.92)	0.76 (0.69-0.84)
n/No.	110/119	29/47	110/128	29/38
DE	0.49 (0.40-0.58)	0.79 (0.67-0.90)	0.85 (0.77-0.94)	0.38 (0.26-0.49)
n/No.	58/119	37/47	58/68	37/98

AWM indicates inducible abnormal wall motion; AWM-D, abnormal wall motion at dipyridamole stress; AWM-rest, abnormal wall motion at rest; CI, confidence interval; DE, delayed enhancement; inducible PD, perfusion deficit; NPV, negative predictive value; PPV, positive predictive value.

per segment), and male gender (5.67 [2.02-15.93]; $P=.001$) were the only variables independently related to CAD.

Extent of Ischemia

The 166 patients were categorized according to the ischemic cascade into the above defined groups. Group 1 (n=37), Group 2 (n=76), and Group 3 (n=53) (Figure 3). The percentage of an abnormal angiography in these 3 groups rose progressively (22%, 79%, 96%, respectively; $P<.0001$ for the trend) (Figure 3A). Throughout the 3 groups, the extent of hypoperfused segments (0.5 [0.8], 6.2 [2.62], 7.4 [3.4]; $P<.0001$ for the trend) (Figure 3B) and the number of diseased vessels increased gradually (0.4 [0.7], 1.4 [1.0], 1.8 [0.9]; $P<.0001$ for the trend) (Figure 3C). When compared to group 2, patients in group 3 had a significantly higher prevalence of CAD ($P=.005$), a larger extent of hypoperfused segments ($P=.044$), and more vessels were affected ($P=.036$) (Figure 3).

In multivariate analysis adjusted for clinical parameters, patients in group 3 had a more than 2-fold higher risk of having a pathologic angiogram than patients in group 2 (2.34 [1.07-5.13]; $P=.034$). A logistic regression model was created first using a combination of only PD and clinical parameters and secondly adding the information of inducible AWM. Figure 4 shows the C-statistic analysis for the diagnostic accuracy of this approach for the detection of CAD. The addition of inducible AWM to PD and clinical parameters afforded an incremental diagnostic value by increasing the area under the curve from 0.829 to 0.876 ($P=.0277$).

DISCUSSION

Using a comprehensive approach of 5 CMR-derived parameters, our study shows that inducible AWM by dipyridamole offers additional diagnostic value to perfusion data for the detection of angiographically significant lesions in patients presenting with chest pain and with a high probability of CAD. Additional assessment of inducible AWM allows the identification of a group of patients with a higher probability of having angiographic CAD and a larger extent of ischemia in terms of hypoperfused segments and number of affected vessels.

Myocardial Perfusion Imaging

Since the advent of myocardial perfusion imaging, the focus of vasodilator stress CMR has shifted from the detection of inducible AWM to the detection of PD. Indeed, there are few CMR studies evaluating the diagnostic value of vasodilator inducible AWM for detecting CAD.^{9,14} PD is usually the consequence of significant epicardial coronary artery stenosis with a certain limitation due to microvascular disease^{15,16} and collateral circulation¹⁷ and therefore can be used to non-invasively diagnose and assess the severity of a luminal narrowing in CAD. In this study we used a widely accepted qualitative method by visual analysis. Using this approach, earlier studies have obtained encouraging results for diagnosing angiographic significant CAD.^{5,13,18,19} In our series of patients, we could demonstrate a comparable diagnostic performance of PD for detection of CAD with a sensitivity of 0.92 and a specificity of 0.62. The presence of a PD is a very

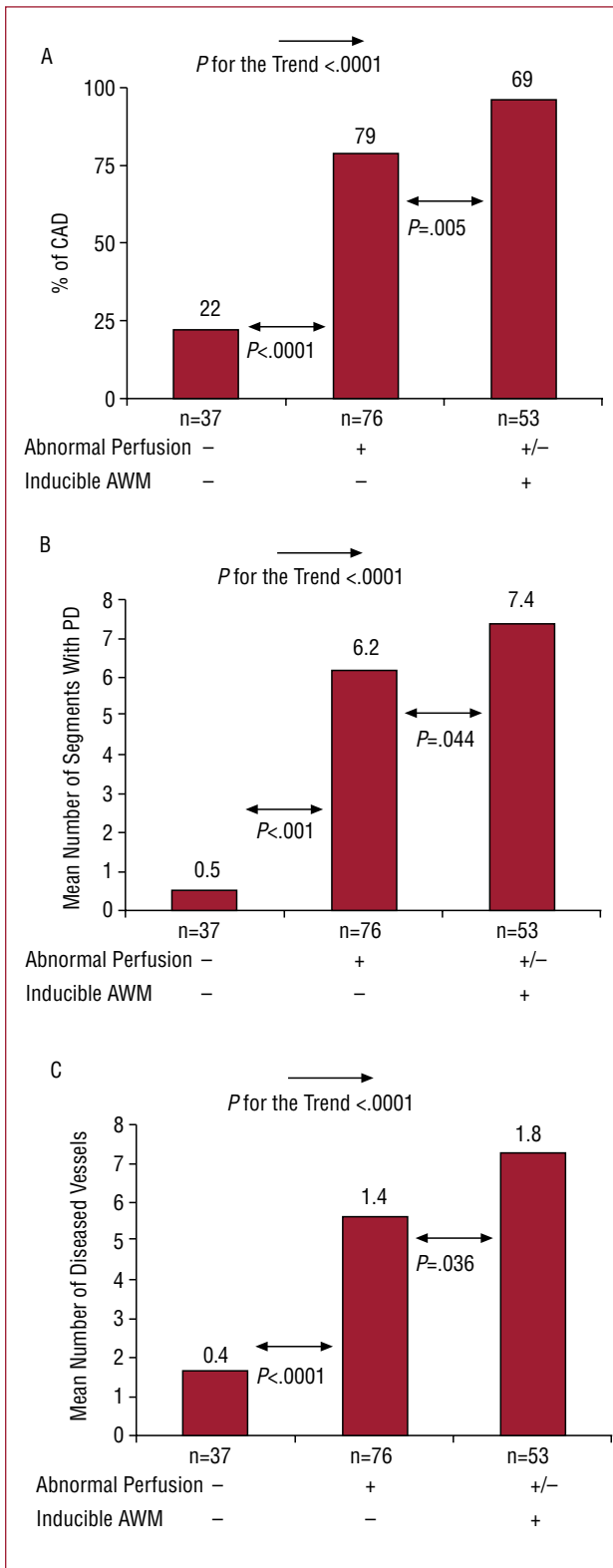


Figure 3. Percentage of CAD and extent of ischemia depending on the 3 groups. A: percentage of coronary artery disease. B: number of hyperperfused segments. C: number of diseased vessels. - indicates index absent; +, index present; +/-, index may be present or absent; AWM, abnormal wall motion; CAD, coronary artery disease; PD, perfusion deficit.

sensitive but in some cases a less specific parameter for the presence of a flow limiting stenosis at stress, due to overestimation of clinical significance of the ischemia detected.²⁰

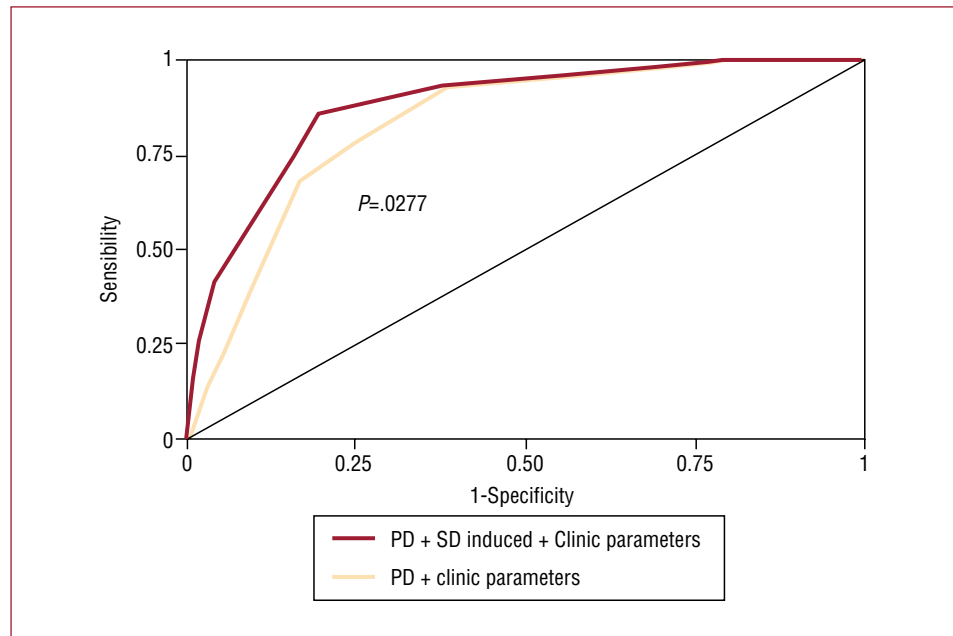
Pathophysiological Considerations. Role of the “Ischemic Cascade”

With increasing severity, myocardial ischemia leads from myocardial perfusion abnormalities to the occurrence of diastolic and systolic AWM and electrocardiographic changes and finally anginal symptoms, a sequence usually referred to as “the ischemic cascade.”^{6,7} With pharmacological stress CMR it is possible to assess 2 of these steps of the ischemic cascade; inducible AWM and the PD preceding it. Consequently in our study, 96% of the patients with inducible AWM presented an abnormal perfusion study. Inducible AWM was not a sensitive but a highly specific parameter with an excellent positive predictive value. In fact only 2 patients displaying inducible AWM did not have severe angiographic lesions. One case was a female patient who had 3 patent coronary bypass grafts on 3 occluded coronary arteries and the other case was a man who had a 60% lesion in the territory of inducible AWM. After adjusting for clinical characteristics and CMR parameters the occurrence of inducible AWM afforded independent additional diagnostic value. Indeed, patients with inducible AWM had a 2-fold higher probability of having a pathologic angiography than did patients with only an abnormal perfusion study.

Patient Classification

From a pathophysiological point of view, this study validates the ischemic cascade by allowing the classification of patients according to the severity of ischemia. By applying inducible AWM, it was possible to identify a group of patients displaying more hypoperfused segments and more diseased vessels. It has been shown that patients with inducible AWM are also at highest risk for adverse outcome and benefit most from revascularization.²⁰ Moreover, our results are in line with data derived from a recent meta-analysis comparing myocardial perfusion imaging with AWM assessed by stress echocardiography. This meta-analysis concludes that perfusion imaging is a sensitive modality with a somewhat low specificity for the detection of CAD while the contrary is true for AWM assessed by stress echo.²¹ Our study demonstrates that using CMR, inducible AWM offers additional diagnostic value in combination with perfusion data, making stress CMR a truly comprehensive approach in the evaluation of ischemia. PD, since it occurs early in the

Figure 4. C-statistic of the diagnostic accuracy for the detection of coronary artery disease using abnormal perfusion and inducible AWM. The clinical variables entered in the logistic regression model were gender, hypertension, and left ventricular ejection fraction. Of the clinical parameters only gender remained in the final model. The model including perfusion deficit and clinical parameters yielded an area under the curve (AUC) of .829. The addition of inducible AWM (in more than 1 segment) afforded an incremental diagnostic value, increasing the AUC to 0.876 ($P=.028$). AWM indicates abnormal wall motion; PD, perfusion deficit; SD, systolic dysfunction



ischemic cascade, is very sensitive for the detection of ischemia, nevertheless due to detection of clinically irrelevant perfusion deficits and susceptibility to artifacts can yield false positive results. Inducible AWM with dipyridamole mainly occurs in severe epicardial stenosis (>75%). The low sensitivity might be owed to worse detection of lesser grade stenosis. Thus, inducible AWM might balance out the lack of specificity of perfusion data.

Different Pharmacological Stressors

The diagnostic and prognostic usefulness of dobutamine stress CMR has already been validated.^{9,22} Dobutamine more frequently provokes systolic dysfunction than vasodilators. However, as a consequence of the resulting high heart rate, dobutamine is not the ideal stressor to evaluate perfusion due to the inherent difficulties to reconstruct perfusion images when cardiac cycles shorten. Inducible AWM using vasodilators is not a frequent phenomenon and when it occurs it relates to severe ischemia. Paetsch et al⁹ observed that adenosine-inducible AWM occurred in segments with at least 75% transmural perfusion deficit and related to high grade (>75%) coronary stenosis. In contrast, dobutamine-induced AWM was observed even in areas without perfusion deficit and related to less severe (>50%) coronary stenosis.

Therefore, the use of dipyridamole, albeit being less potent than dobutamine for inducing AWM, might be advantageous for identifying a group

of patients with severe and clinically significant ischemia, and by that might improve of specificity in stress CMR. Moreover, the additional diagnostic value of inducible AWM that could be demonstrated in the present study can be obtained in a very short period of time (during a 14 second breath hold) not prolonging examination time, thereby making this approach easily applicable in clinical practice.

Study Limitations

Our study is limited by its retrospective nature. Out of all 600 patients who underwent a dipyridamole stress CMR study those patients with an abnormal CMR study were more likely to undergo coronary angiography than were patients with an entirely normal CMR examination. This probably limits the generalizability of our data and might account for the high prevalence of CAD and the rather low specificity of PD in our study.

CONCLUSIONS

Using dipyridamole stress CMR, adding inducible AWM to perfusion imaging offers additional diagnostic value for the detection of CAD in patients presenting with chest pain and known or suspected CAD. According to the ischemic cascade, the presence of inducible AWM allows the identification of a group of patients with more severe ischemia and with a higher probability of having angiographic CAD.

REFERENCES

- Barkhausen J, Hunold P, Jochims M, Debatin JF. Imaging of myocardial perfusion with magnetic resonance. *J Magn Reson Imaging*. 2004;19:750-7.
- Nagel E, Lehmkuhl HB, Bocksch W, Klein C, Vogel U, Frantz E, et al. Noninvasive diagnosis of ischemia-induced wall motion abnormalities with the use of high-dose dobutamine stress MRI: comparison with dobutamine stress echocardiography. *Circulation*. 1999;99:763-70.
- Hundley WG, Hamilton CA, Thomas MS, Herrington DM, Salido TB, Kitzman DW, et al. Utility of fast cine magnetic resonance imaging and display for the detection of myocardial ischemia in patients not well suited for second harmonic stress echocardiography. *Circulation*. 1999;100:1697-702.
- Nagel E, Klein C, Paetsch I, Hettwer S, Schnackenburg B, Wegscheider K, et al. Magnetic resonance perfusion measurements for the noninvasive detection of coronary artery disease. *Circulation*. 2003;108:432-7.
- Wolff SD, Schwitter J, Coulden R, Friedrich MG, Bluemke DA, Biederman RW, et al. Myocardial first-pass perfusion magnetic resonance imaging: a multicenter dose-ranging study. *Circulation*. 2004;110:732-7.
- Nesto RW, Kowalchuk GJ. The ischemic cascade: temporal sequence of hemodynamic, electrocardiographic and symptomatic expressions of ischemia. *Am J Cardiol*. 1987;59: C23-30.
- Kaandorp TA, Lamb HJ, Bax JJ, van der Wall EE, De RA. Magnetic resonance imaging of coronary arteries, the ischemic cascade, and myocardial infarction. *Am Heart J*. 2005;149: 200-8.
- Ishida N, Sakuma H, Motoyasu M, Okinaka T, Isaka N, Nakano T, et al. Noninfarcted myocardium: correlation between dynamic first-pass contrast-enhanced myocardial MR imaging and quantitative coronary angiography. *Radiology*. 2003;229:209-16.
- Paetsch I, Jahnke C, Wahl A, Gebker R, Neuss M, Fleck E, et al. Comparison of dobutamine stress magnetic resonance, adenosine stress magnetic resonance, and adenosine stress magnetic resonance perfusion. *Circulation*. 2004;110:835-42.
- Bodí V, Sanchis J, López-Lereu MP, Núñez J, Mainar L, Monmeneu JV. Prognostic value of dipyridamole stress cardiovascular magnetic resonance imaging in patients with known or suspected coronary artery disease. *J Am Coll Cardiol*. 2007;50:1174-9.
- Cerqueira MD, Weissman NJ, Dilsizian V, Jacobs AK, Kaul S, Laskey WK, et al. Standardized myocardial segmentation and nomenclature for tomographic imaging of the heart. A statement for healthcare professionals from the Cardiac Imaging Committee of the Council on Clinical Cardiology of the American Heart Association. *Int J Cardiovasc Imaging*. 2002;18:539-42.
- Schiller NB, Shah PM, Crawford M, deMaria A, Devereux R, Feigenbaum H, et al. Recommendations for quantitation of the left ventricle by two-dimensional echocardiography. American Society of Echocardiography Committee on Standards, Subcommittee on Quantitation of Two-Dimensional Echocardiograms. *J Am Soc Echocardiogr*. 1989;2:358-67.
- Cury RC, Cattani CA, Gabure LA, Racy DJ, de Gois JM, Siebert U, et al. Diagnostic performance of stress perfusion and delayed-enhancement MR imaging in patients with coronary artery disease. *Radiology*. 2006;240:39-45.
- Baer FM, Smolarz K, Jungehulsing M, Theissen P, Sechtem U, Schicha H, et al. Feasibility of high-dose dipyridamole-magnetic resonance imaging for detection of coronary artery disease and comparison with coronary angiography. *Am J Cardiol*. 1992;69:51-6.
- Sandstede JJ, Lipke C, Beer M, Harre K, Pabst T, Kenn W, et al. Analysis of first-pass and delayed contrast-enhancement patterns of dysfunctional myocardium on MR imaging: use in the prediction of myocardial viability. *AJR Am J Roentgenol*. 2000;174:1737-40.
- Panting JR, Gatehouse PD, Yang GZ, Grothues F, Firmin DN, Collins P, et al. Abnormal subendocardial perfusion in cardiac syndrome X detected by cardiovascular magnetic resonance imaging. *N Engl J Med*. 2002;346:1948-53.
- Cullen JH, Horsfield MA, Reek CR, Cherryman GR, Barnett DB, Samani NJ. A myocardial perfusion reserve index in humans using first-pass contrast-enhanced magnetic resonance imaging. *J Am Coll Cardiol*. 1999;33:1386-94.
- Pons LG, Carreras F, Leta R, Pujadas S, García PJ. Estudio de perfusión miocárdica por cardiioresonancia magnética: comparación con la angiografía coronaria. *Rev Esp Cardiol*. 2004;57:388-95.
- Pilz G, Bernhardt P, Klos M, Ali E, Wild M, Hofling B. Clinical implication of adenosine-stress cardiac magnetic resonance imaging as potential gatekeeper prior to invasive examination in patients with AHA/ACC class II indication for coronary angiography. *Clin Res Cardiol*. 2006;95:531-38.
- Bodí V, Sanchis J, López-Lereu MP, Núñez J, Mainar L, Monmeneu JV, et al. Prognostic and therapeutic implications of dipyridamole stress cardiovascular magnetic resonance on the basis of the ischemic cascade. *Heart*. 2009;95:49-55.
- Schinkel AF, Bax JJ, Geleijnse ML, Boersma E, Elhendy A, Roelandt JR, et al. Noninvasive evaluation of ischaemic heart disease: myocardial perfusion imaging or stress echocardiography? *Eur Heart J*. 2003;24:789-800.
- Hundley WG, Morgan TM, Neagle CM, Hamilton CA, Rerkpattanapit P, Link KM. Magnetic resonance imaging determination of cardiac prognosis. *Circulation*. 2002;106:2328-33.