571

Routine application of diffusion weighted imaging during brain MR: experience on 314 consecutive cases

R. Parodi[1,2], M. Pensa[1], L. Castelletti[1], L. Castellan[1,2]; [1]*UO Neuroradiologia Diagnostica e Terapeutica, AOU San Martino di Genova, Genova, Italy,* [2]*Centro RM di Ricerca sulle Malattie del Sistema Nervoso Centrale, Genova, Italy.*

Purpose: in this paper we try to assess the diagnostic utility of the Diffusion Weighted Imaging (DWI) from a single center series of brain MR.
Subjects and methods: we retrospectively evaluated 314 consecutive brain MR with DWI acquisition, performed on a 1.5T GE Signa Excite equipment. DWI sequence was obtained using: TR 8000ms, TE 83ms, 128*128 matrix, NEX 2, B 1000ms. From the clinical suspects, patients were divided in 3 groups: group 1 vascular lesions (142 patients), group 2 neoplastic lesions (31 patients), group 3 miscellaneous (migraine, multiple sclerosis, EEG changes, cranial nerve palsy) (141 patients).
Results: DWI sequence resulted always useful, as expected, in group 1 because of the opportunity of giving temporal informations of vascular lesions (hyperacute, acute, subacute and chronic lesions). In group 2, DWI was useful in 8/31 (25.8%) cases, particularly DWI revealed 7 embriogenetic cyst and one abscess among neoplasms. In group 3, DWI gave additional informations in 7/141 (5%) cases: 4 unexpected recent vascular lesions (2 of them of cardio-embolic type with synchronous lesions in different vascular territories) and 3 cases of prion diseases (Creutfeld-Jacobs disease) without EEG changes. On the whole, from a diagnostic point of view DWI was considered useful in 157/314 cases (50%).
Conclusion: DWI is confirmed as a useful and little time-expensive tool in discovering and evaluating vascular lesions, but also as a valuable tool in other pathologies. DWI sequence lasted only 64 sec, a negligible time in a routine brain MR. Although an overall low utility among group 2 and 3, DWI gave additional information which modified diagnosis, therapy and/or prognosis in 15/172 cases (8.7%).

572

Voxel-based diffusion: a temporal lobe analysis in schizophrenia

G. Garcia-Marti[1], J. Carbonell-Caballero[1], L. Marti-Bonmati[2], J. Manjon[1], J. J. Lull[1], M. De la Iglesia[1], D. Moratal[1], M. Robles[1], J. Sanjuan[3]; [1]*Bioengineering, Electronic and Telemedicine, Politechnical University of Valencia, Valencia, Spain,* [2]*Department of Radiology, Dr Peset University Hospital and Quiron Clinic, Valencia, Spain,* [3]*Psychiatric Unit, University of Valencia School of Medicine, Valencia, Spain.*

Introduction: Schizophrenia is a heterogeneous disorder affecting almost 1% of the population. Neuroimaging studies have revealed temporal lobe abnormalities in schizophrenic patients when compared with healthy subjects. In this context, Diffusion Tensor Imaging (DTI) is being increasingly used to study structural abnormalities which can be detected by analyzing water diffusion changes. We propose a new voxel-wise diffusion method whose analysis is focused in temporal lobe area, and is easily comparable with other previous structural findings in schizophrenia using voxel-based morphometry (VBM).
Subjects and methods: A group of 7 (aged 42 ± 8) right handed male patients with DSM-IV schizophrenia with persistent auditory hallucinations and 11 (aged 32 ± 8) healthy subjects were compared. Diffusion Weighted Images (DWI) (Turbo Spin Echo sequence, TR = 4197 ms, TE = 95 ms, matrix size = 256x256, 24 slices) were acquired on a 1.5 Tesla magnet. Mean diffusivity (ADCm) and fractional anisotropy (FA) maps were computed from DWI. Custom ADCm and FA templates were created and all volumes were spatially normalized to them. Bilateral middle and superior temporal lobe were defined as the region of interest (ROI). Finally, the ROI voxel-based analysis was performed under the General Linear Model (GLM) framework by using SPM.
Results: Significant alterations both in ADCm and FA maps were observed (Figure 1). Patients showed highly ADCm increases and significant FA reductions in the gray matter (GM) of the left middle temporal lobe, which are concordant with GM density reduction reported by previous VBM findings (García-Martí et al., 2005). Expectedly no significant decreases in ADCm patients were found (significant threshold was fixed at $p < 0.005$ uncorrected).
Conclusion: We have proposed a new different voxel-based DTI analysis approach which can be potentially applied to future schizophrenia and other MRI studies.
References: García-Martí, G., Lull JJ., Martí-Bonmatí, L., Sanjuan, J., Poyatos, C., Carbonell-Caballero, J., Manjón, JV., Robles, M. 2005. Morphometry in schizophrenic patients with chronic auditory hallucinations. *ESMRMB 2005 Abstracts book* pp 253-253.

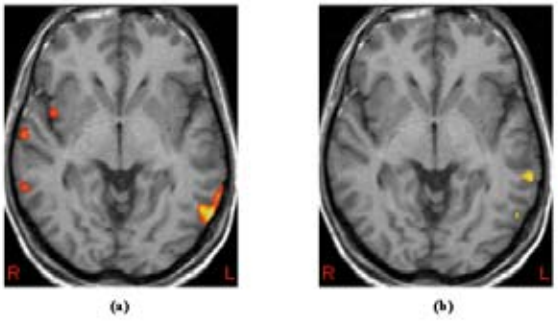

Figure 1. Result maps. (a) ADCm increases in patients versus controls. (b) FA reductions in patients against controls. $p < 0.005$ Uncorrected.

573

Reconstruction of the entire human visual system based on DTI fiber tracking in a single seed region approach

P. Staempfli[1,2], A. Rienmueller[1], **C. Reischauer**[1], P. Boesiger[1], S. Kollias[2]; [1]*Institute for Biomedical Engineering, ETH and University Zurich, Zurich, Switzerland,* [2]*Institute of Neuroradiology, University Hospital of Zurich, Zurich, Switzerland.*

Introduction: Diffusion tensor imaging (DTI) is a MRI-technique, which provides non-invasive, *in-vivo* measurements of the diffusion of water molecules [1]. It allows the reconstruction of white matter fiber tracks by so-called tracking algorithms [2]. Although this technique features strong diagnostic potential for clinical applications, there are still limitations for fiber tracking, especially in complex fiber arrangements, such as axonal crossings. In this study, the entire human visual system is reconstructed on the basis of the advanced Fast Marching (aFM) method [3] and compared to known anatomy. A particular region of interest was the optic chiasm, a region that features extensive axonal crossings.