(MLV) and volume velocities (VV) of CSF in intradural space were evaluated. Stroke volume was calculated as area under absolute value of volume velocity per cardiac cycle.

Results: We visualized and estimated the CSF passage through the aqueduct cerebry, the forth ventricle, cistern magna, foramen magnum and intradural space. The SV at the level of C2-C3 intervertebral disk were 1.06±0.47 ml, 0.31±0.24 ml and 0.64±0.29 ml, accordingly for healthy volunteers, patients with Chiari I malformation before and after surgery ($p<0.03$ and $p>0.12$, accordingly). MeanLV amplitudes were 2.28±0.77 cm/sec, 0.72±0.34 cm/sec and 1.66±1.07 cm/sec, ($p<0.01$ and $p>0.2$). MLV amplitudes were 7.10±0.87 cm/sec, 5.13±1.20 cm/sec and 9.87±7.78 cm/sec, ($p<0.1$ and $p>0.5$). MeanLV were 0.61±0.27 cm/sec, 0.20±0.13 cm/sec, 0.47±0.20 cm/sec, ($p<0.03$ and $p>0.3$). VV were 87.09±44.18 ml/min, 23.97±13.33 ml/min and 56.46±24.02 ml/min, ($p<0.03$ and $p>0.2$). MLV were 2.41±0.67 cm/sec, 1.99±0.35 cm/sec and 3.82±3.28 cm/sec, ($p>0.1$ and $p>0.5$).

Conclusion: Phase-contrast MRI allows visualize CSF passage and evaluate quantitative values of CSF pulsative motion for healthy volunteers and patients with Chiari I malformation before and after surgical treatment. Phase-contrast MRI at the level of C2-C3 intervertebral disk showed the decreasing of SV ($p<0.03$), meanLV amplitude ($p<0.01$), MLV amplitude ($p<0.1$), meanLV ($p<0.03$), VV ($p<0.03$) for patients with Chiari I before surgery. Comparison between healthy volunteers and patients after surgery doesn't show any significant difference in accordance with positive neurological symptomatic.

References:

[1] Hofmann E. et al. AJNR. 2000. V. 21. P. 151-158.
[2] Armonda R. et al. Neurosurgery. 1994. V.35. P. 214-224.
[3] Brugieres P. et al. AJNR. 2000. V. 21(10). P. 1785-92.
[4] Haughton V. et al. AJNR. 2003. V. 24. P. 169-176.
[5] Dolar M. et al. AJNR. 2004. V. 25. P. 142-145.

454

Partial volume effect and aliasing correction in PC-MRI analysis of cerebrospinal fluid flow

D. Moratal-Pérez[1], Y. N. Flórez Ordoñez[1], J. Forner-Giner[2], E. Arana[2], L. Martí-Bonmatí[2], J. Millet-Roig[1]; [1]*BET Research Group, Universitat Politécnica de Valencia, Valencia, SPAIN,* [2]*Radiology Department, Clínica Quirón, Valencia, SPAIN.*

Purpose: There is a great diversity of results at the moment to carry out a quantitative analysis of cerebrospinal fluid (CSF) within the cerebral aqueduct by means of MRI due to the observer-related variability to select the region of interest (ROI). Main source of errors are related to the presence of partial volume (PV) effects and aliased pixels [1,2]. Our purpose is to develop a reproducible method that permits to automatically define a ROI, applying a background correction and a correction of the aliased pixels in order to accurately calculate parameters of CSF flow.

Subjects and Methods: MR examinations were performed using a 1.5 T Philips Gyroscan Intera scanner with a phase contrast sequence. Image parameters were: 256 phase encodings, FOV=160 mm, 3 mm slice thickness, TR=53 ms, TE=11 ms, NSA=2, flip angle=15º and 20-27 frames per cardiac cycle.

The model has been validated in 20 patients, 11 men and 9 women, of age range: 45-79 years old. From these 20 patients: 13 were healthy subjects, 4 with clinical symptoms and MR findings of normal pressure hydrocephalus (NPH); 3 patients had other symptoms.

Results: The model is highly reproducible, the aliased pixels are automatically detected and corrected by means of 3D visualization (Fig1). An average value of offset per frame in the mesencephalon is used to correct the PV (Fig 2) in order to automatically select the ROI and to calculate the different parameters.

The 4 patients with clinical symptoms and MR findings of NPH had a mean flow of 4.9 ml/s ± 3.2 ml/s while the stroke volume was 43.3 µl ± 12.4 µl. The thirteen healthy subjects had a mean flow of 0.9 ml/s ±1.2 ml/s; the stroke volume was 6.5 µl ±9.5 µl.

The three patients with other pathologies -non related with CSF flow- had a mean flow of 0.9 ml/s ± 0.7 ml/s and a stroke volume of 5.7 µl ± 5.2 µl. The difference between groups was greatly significant.

Conclusions: Our tool makes the measurements independent of the operator, generalizing the calculus of flow parameters with great consistency.

A clear difference of flow and volume per cycle through the cerebral aqueduct has been observed between patients with clinical symptoms and MR findings of NPH patients with other pathologies not related to CSF flow and healthy subjects.

References:

[1] WG Bradley et al. *Radiology* 1986; 159: 611-616.
[2] D Enzmann et al. *Radiology* 1991; 178:467- 474.

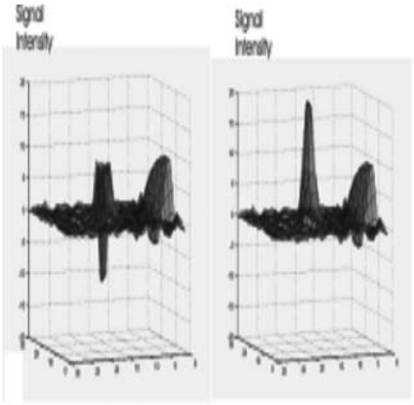



455

Limits for estimation of acceleration from velocity data derivation in hemodynamic studies

F. Buyens[1], O. Jolivet[1], J. Bittoun[2], A. Herment[1]; [1]*U494, Inserm, Paris, FRANCE,* [2]*U2r2m, CNRS, Le Kremlin-Bicêtre, FRANCE.*

Introduction: Differential pressure maps can be extracted from MR imaging data using the Navier-Stokes (equation1).

$$\nabla \mathbf{P} = -\rho \mathbf{a} + \rho \mathbf{g} + \mathbf{v}.\nabla \mathbf{v}$$

For reason of easily accessible velocity data **v**, the acceleration **a** is often derived from phase contrast velocity data (equation2).

$$\mathbf{a} = \frac{\partial \mathbf{v}}{\partial t} + \mathbf{v}.\nabla \mathbf{v}$$